

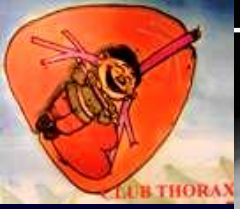

J. GIRON – P. FAJADET

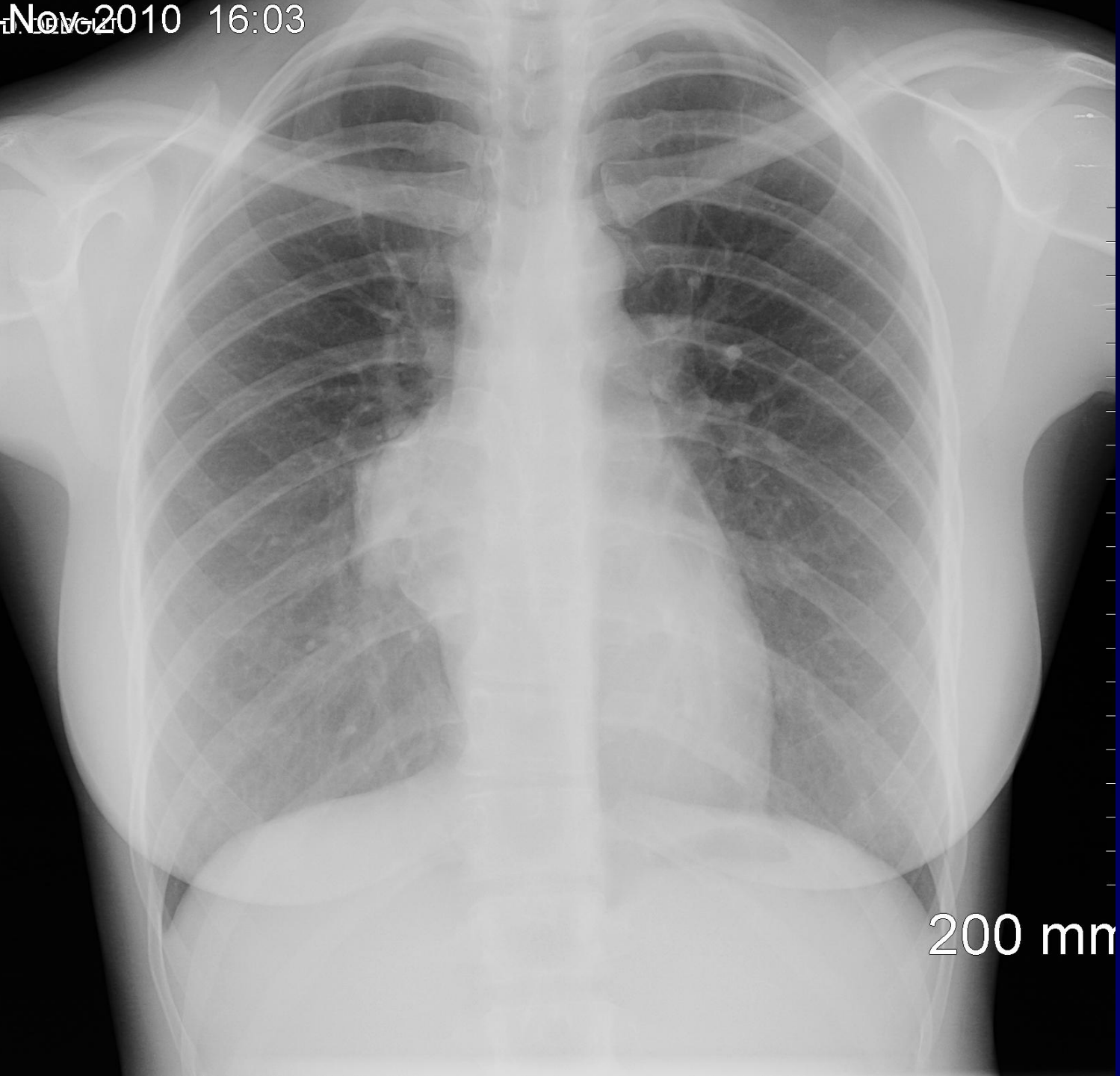
Femme de 30 ans

Fortuit

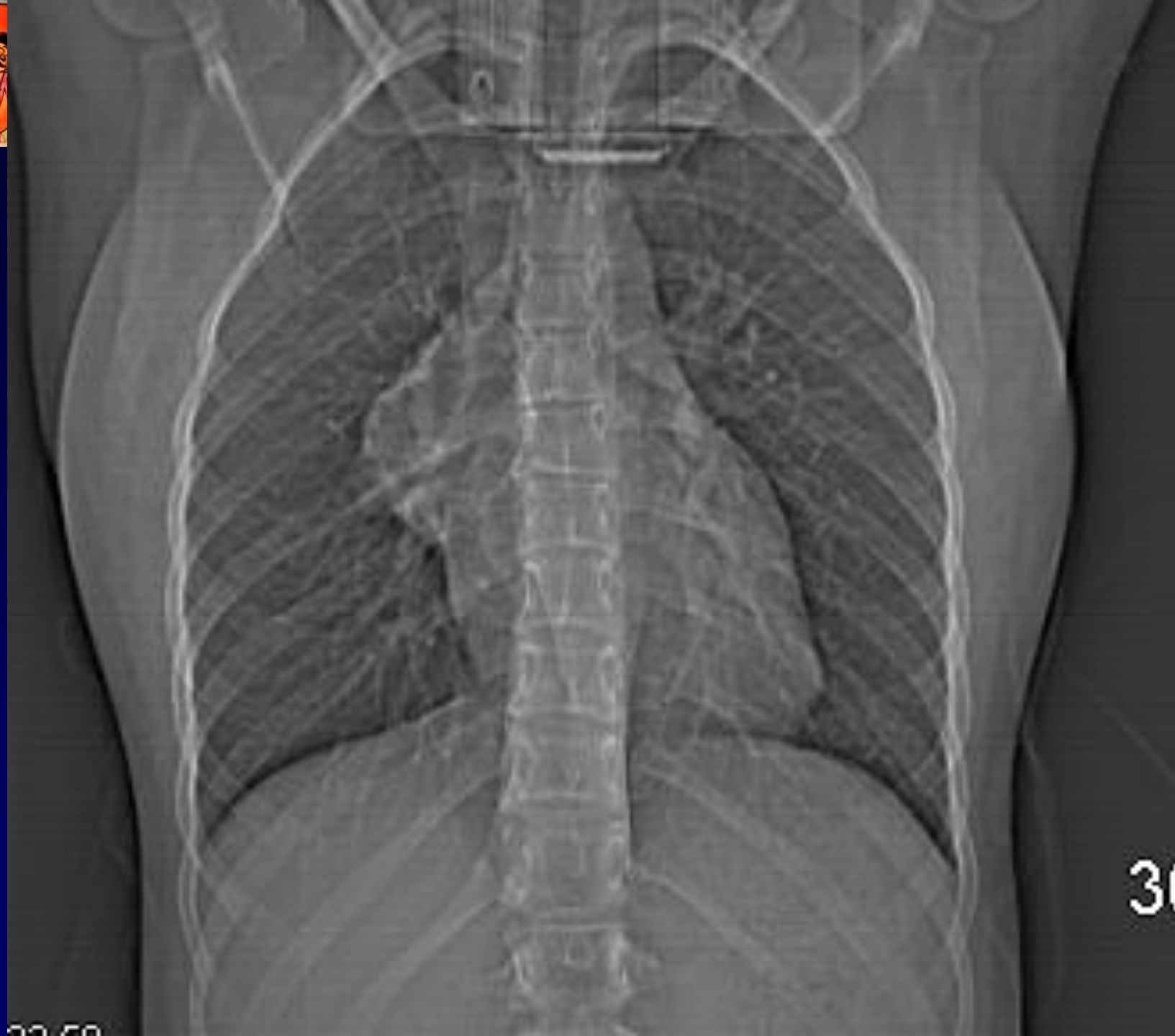RT systématique



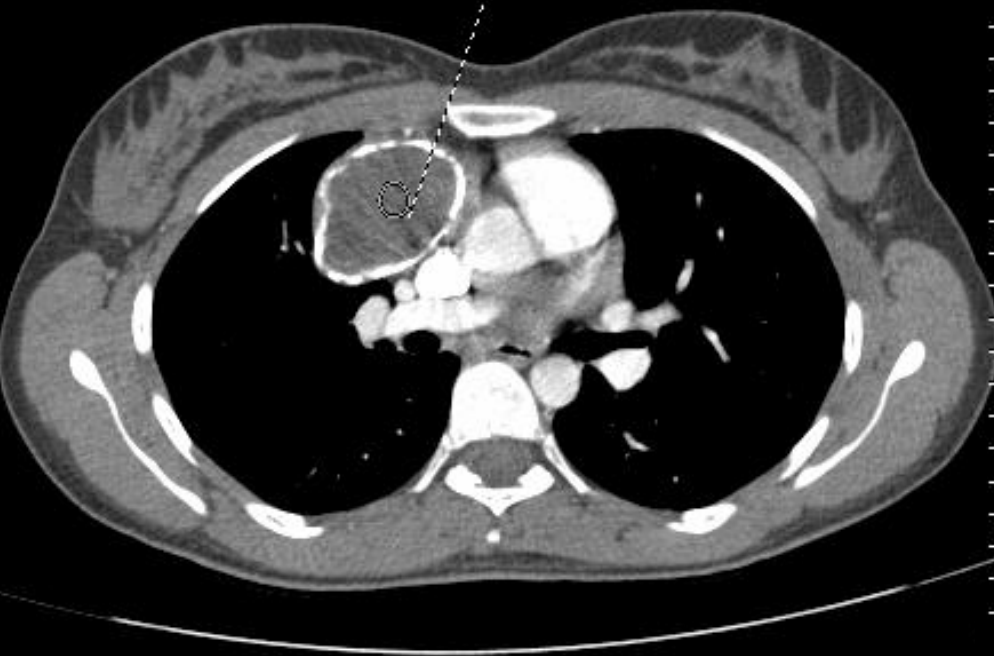Nov 2010 16:03



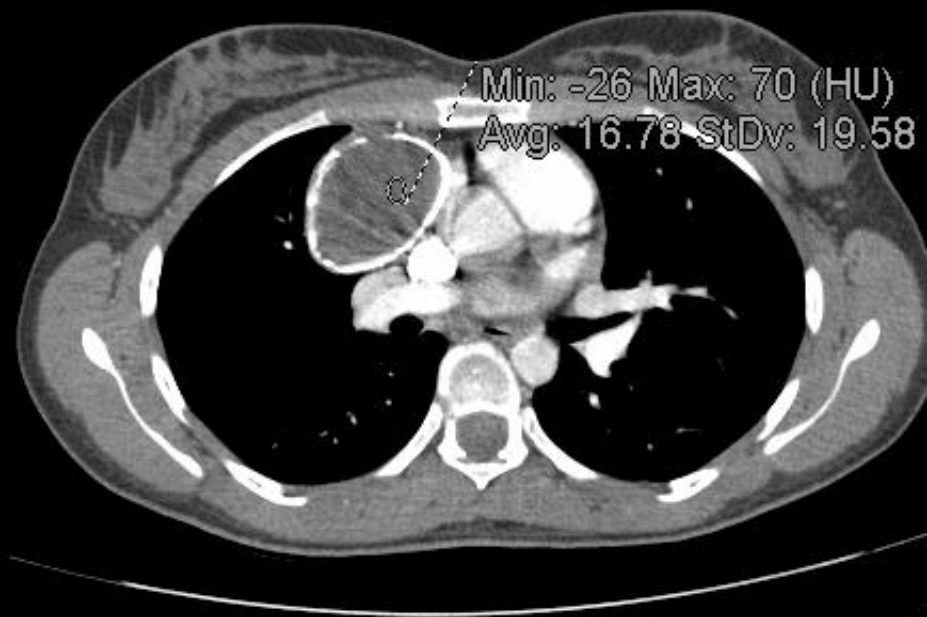
200 mm



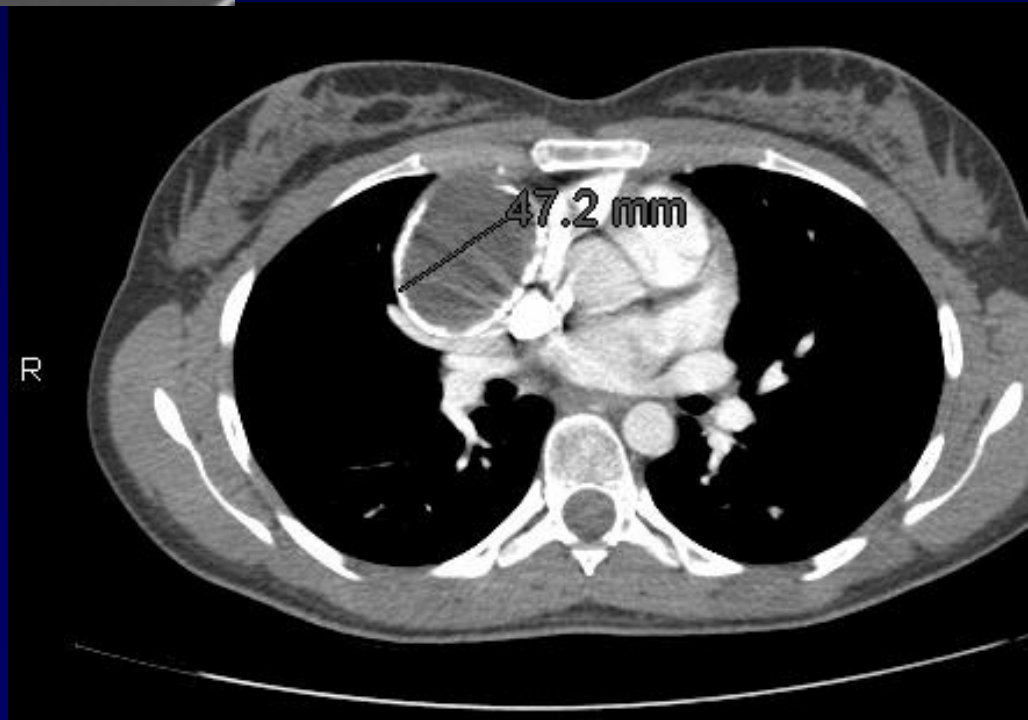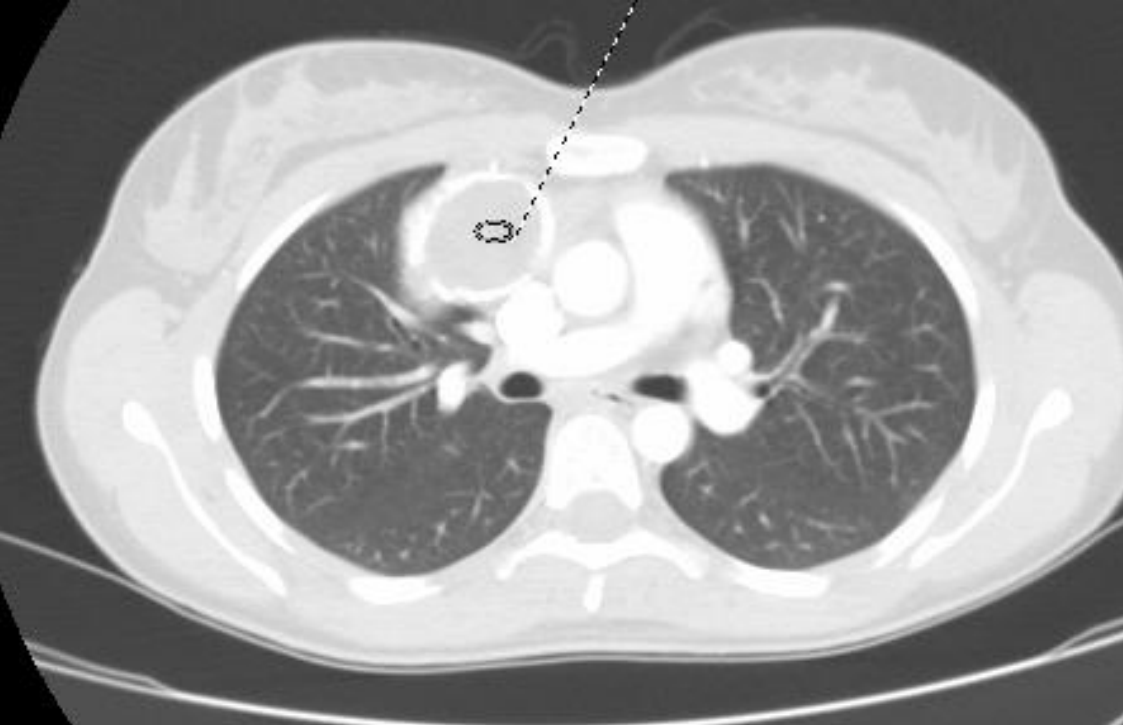
31

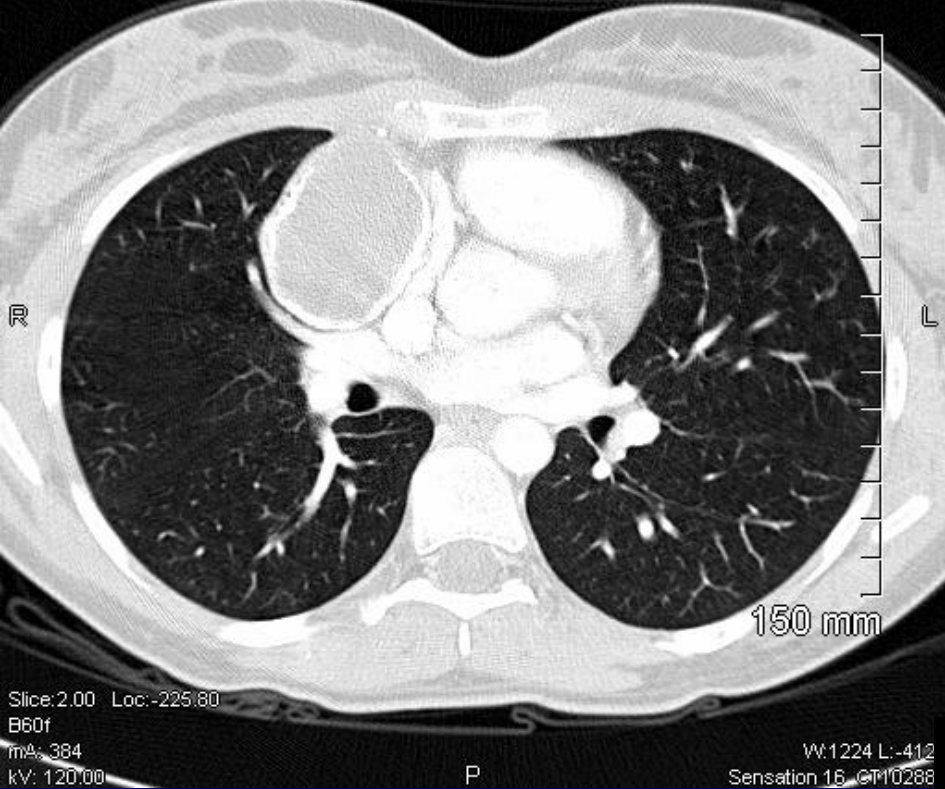


200 m



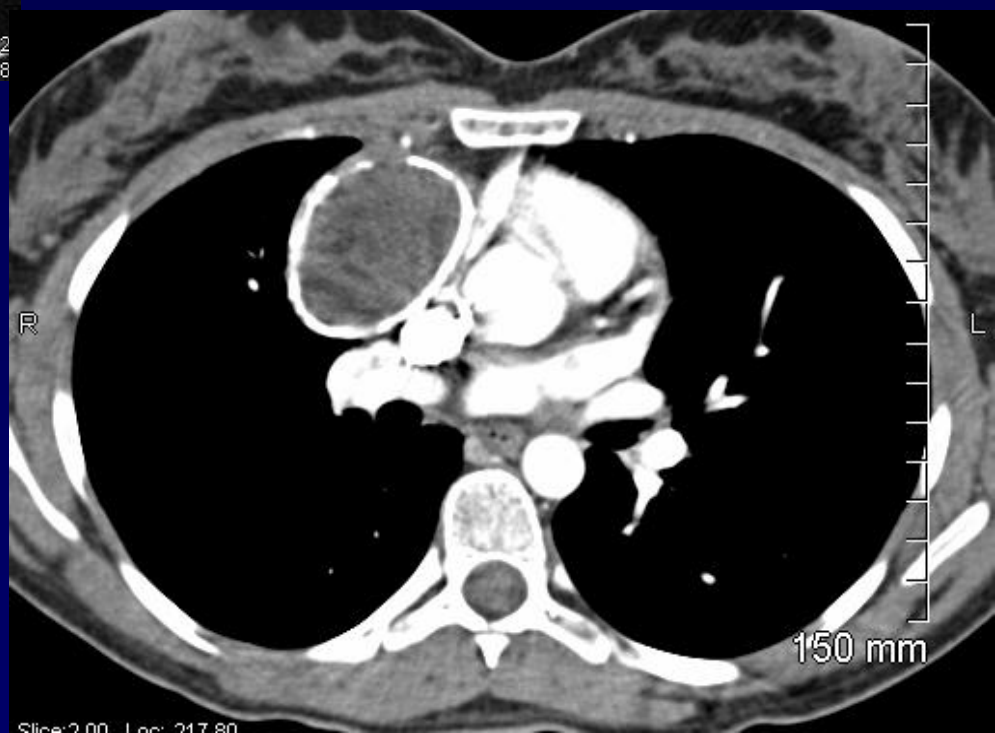
200 m





Slice: 2.00 Loc: -225.80
B60f
mAs: 384
kV: 120.00

W: 1224 L: -412
Sensation 16 CM10288



Slice: 2.00 Loc: -217.80



Diagnostic ?



Diagnostic différentiel ?

Kyste Hydatique ???

Foie: - ,

Séro :-,

Ne calcifie pas (+ ou -)



Diagnostic

Tératome Thymique bénin